



PATIENT

Cameo Martinez

PRESENTING CLINICAL SIGNS

History: Grade 2-3/6 heart murmur. Assess prior to dental.

SPECIES

Feline

BREED

DSH

SEX

Male Neutered

AGE

2 years

WEIGHT

12.2lbs

INTERPRETED BY

Maggie Machen Lamy,
DVM, DACVIM
(Cardiology)

IMAGING PERFORMED BY

G. Ferrer, DVM

ECHOCARDIOGRAM FINDINGS

2D, m-mode, color flow and doppler imaging is available. The left ventricular wall is normal in dimension. There is a mildly hyperechoic endocardium consistent with age-related fibrosis. The endocardium also appears mildly remodeled. The papillary muscles appear mildly remodeled. The left atrium is normal in size. Blood flow through the LVOT appears normal with no evidence of obstruction. The right atrium is normal in size. The right ventricle appears normal. The tricuspid valve appears normal in structure and mobility. Trace tricuspid regurgitation. The mitral valve is normal in structure and mobility. No mitral regurgitation. Blood flow through the RVOT is mildly elevated in velocity based upon color flow (not captured on Spectral Doppler), likely secondary to tachycardia creating a benign outflow tract obstruction. No evidence of cardiac tumors or metastatic lesions on this scan.

CARDIAC CHART

FELINE CARDIAC PARAMETERS	BODY WEIGHT (kg)	HR (BPM)	IVSd (cm) (Moise, Pipers)	LVIDd (cm) (Moise, Pipers)	LWVd (cm) (Moise, Pipers)	FS (%)	EF (%)
NORMAL PARAMETER	-----	150-240	0.35-0.55	<2 (mean 1.5)	3.5-0.55	35-67	80-100
PATIENT	5.6	176	0.51	1.52	0.49	63	93
FELINE CARDIAC PARAMETERS	LA/AO (Boon)	LA/AO HEART BASE (Swe) (Abbott)	LA 2D short axis Base view (cm) (Abbott)		LVOT VEL (m/s)	RVOT VEL (m/s)	E max (m/s)
NORMAL	<1.5	<1.3	<1.2		<1.6	<1.3	<0.9
PATIENT	NM	1.2	1.0		0.9	1.2	NM
<p><i>*Note: All measurements based upon multi-modal images and methods. An average value is reported.</i> Adapted from June Boon, Veterinary Echocardiography, 1998 Abbott J & MacLean H JVIM 2006;20: 111-119, Moise et al. Am J Vet Res 47:1476, 1986. Pipers et al. Am J Vet Res 40:882, 1979.</p>							

HOSPITAL NAME

Paseos Veterinary Center

REFERRING VET

Dr. Ferrer

INVOICE

30055

DATE

4/5/23

INTERPRETATION OF THE FINDINGS & FURTHER RECOMMENDATIONS

The only cause of a murmur identified is a heart rate dependent flow obstruction through the right ventricle (DRVOTO), which is a physiologic finding (i.e., benign and of little clinical significance). This type of flow murmur will wax and wane secondary to tachycardia and volume changes. There is mild LV remodeling and fibrosis, which is likely a normal age-related finding. Regardless, the left atrial dimension is normal, and there is minimal risk for complication at this time. No additional abnormalities are seen.

Given these findings, no medications are indicated at this time.

If needed, the risk for general anesthesia is low. Judicious IV fluid use is recommended in any older cat. Additionally a screening blood pressure is recommended prior to general anesthesia.



PATIENT

Cameo Martinez

Risk for complication with steroid use typically follows LA dilation, which in this case is low. That being said, any cat can experience unexpected signs of intolerance and monitoring of RR/RE is advised particularly in the initiation phase.

SPECIES

Feline

Recommend recheck echocardiogram in 1 year to assess for progression or development of disease the pre-existing murmur may mask.

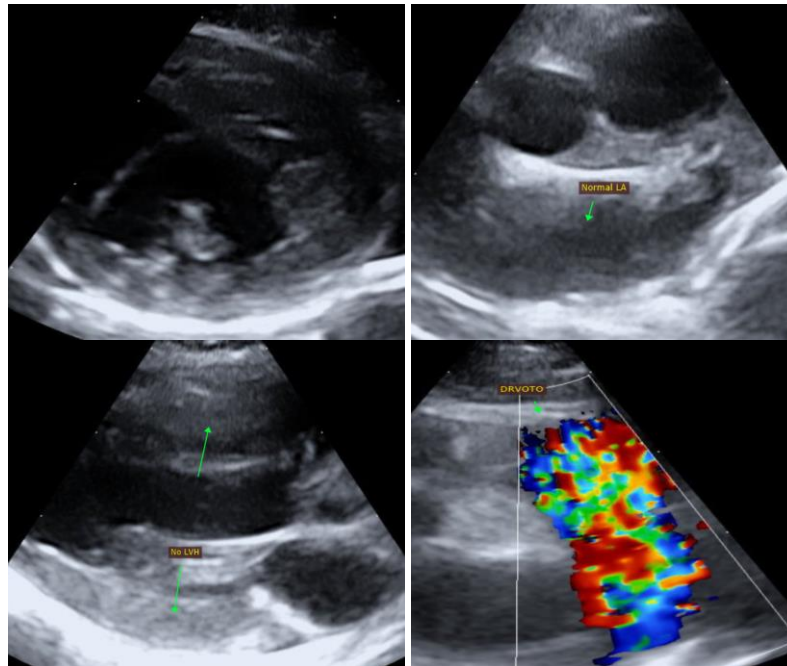
BREED

DSH

IMAGES

SEX

Male Neutered



AGE

2 years

WEIGHT

12.2lbs

INTERPRETED BY

Maggie Machen Lamy, DVM, DACVIM (Cardiology)

The information and recommendations provided are based on the images presented by the referring veterinarian. No evaluation can be communicated regarding pathology that was not visible in the image/video clips provided.

IMAGING PERFORMED BY

G. Ferrer, DVM

Thank you for this referral. This report was generated using transcription software, and minor dictation errors may be present. If the clinical or image interpretation does not parallel your findings or if I can be of any further assistance, please contact me.

HOSPITAL NAME

Paseos Veterinary Center

Maggie Machen Lamy, DVM
Diplomate of the American College of Veterinary Internal Medicine (Cardiology)
info@sonopath.com

REFERRING VET

Dr. Ferrer

INVOICE

30055

DATE

4/5/23